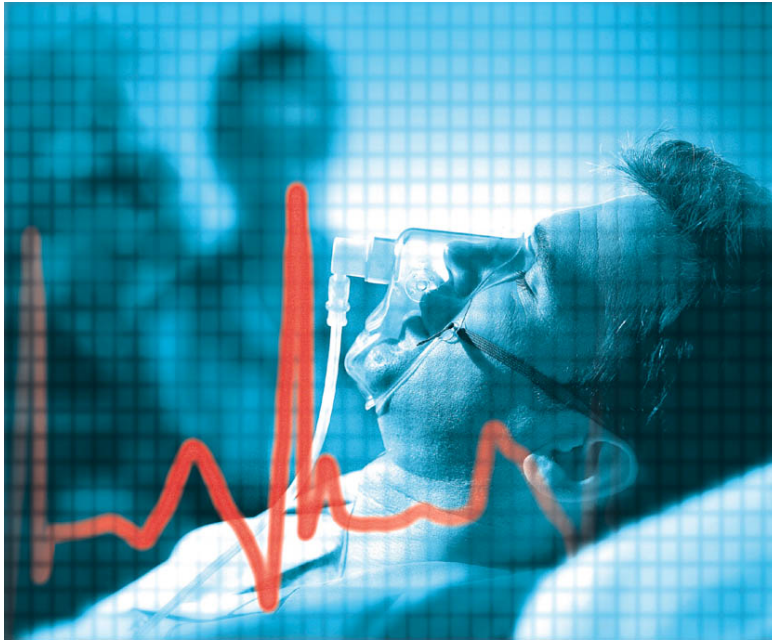

The Six Second ECG



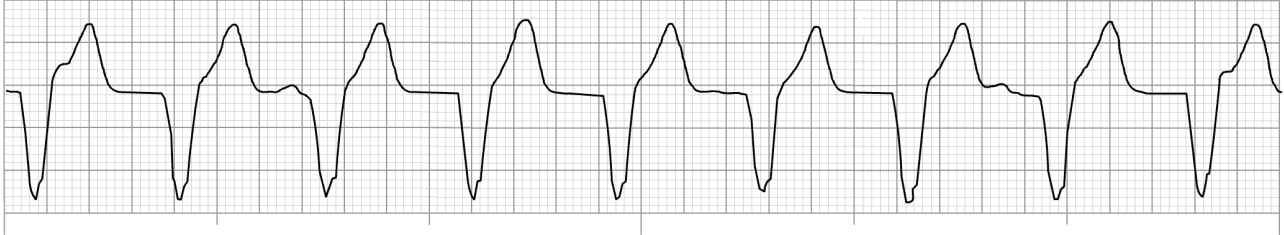ECG Quiz 3A

Version 3.1

The Six Second ECG Quiz 3A (version 3.1)

Please answer the following questions by circling the correct answer on the accompanying answer sheet. **Please do not write on this test booklet.** All rhythms are six second ECGs from lead II.

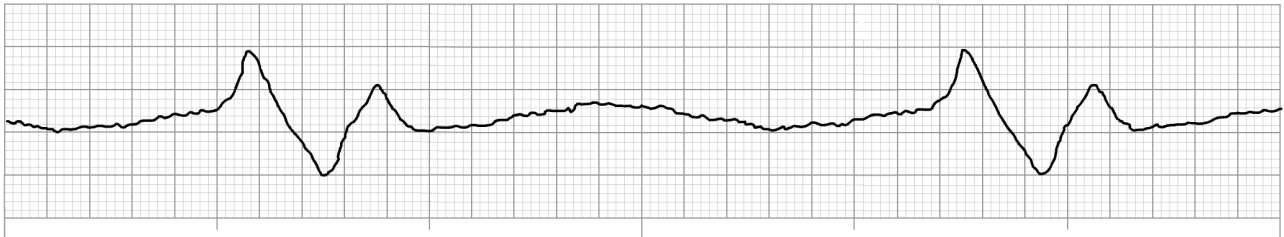
Question 1



This ECG rhythm is called:

- a) Sinus rhythm with aberrant intraventricular conduction
- b) Accelerated idioventricular rhythm
- c) Accelerated junctional rhythm with aberrant intraventricular conduction
- d) Junctional tachycardia

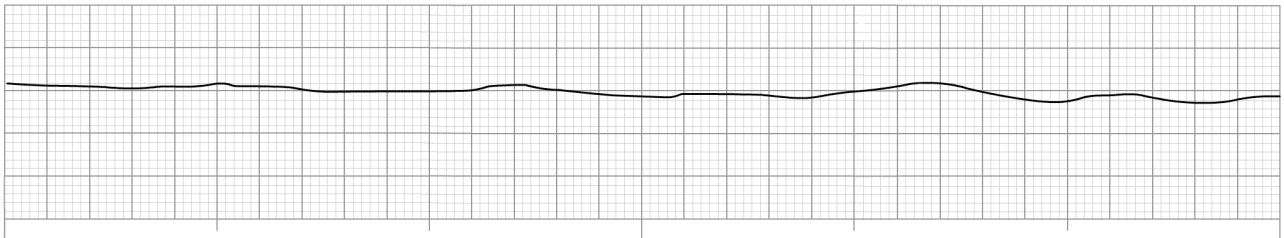
Question 2



This ECG rhythm is called:

- a) Agonal rhythm
- b) Idioventricular rhythm
- c) Junctional bradycardia
- d) Sinus bradycardia with aberrant intraventricular conduction

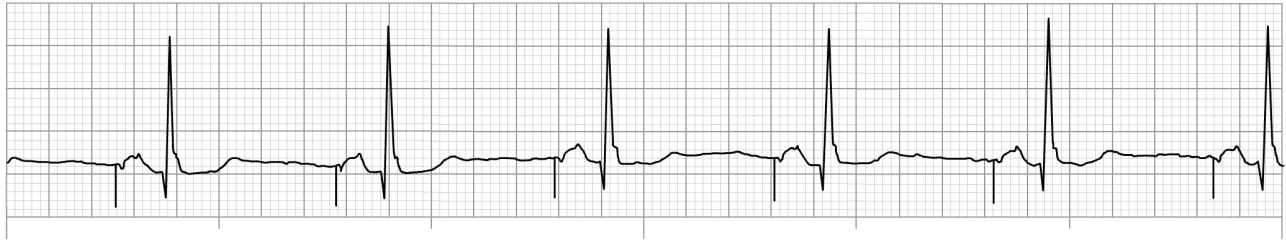Question 3



This ECG rhythm is called:

- a) Fine ventricular fibrillation
- b) Artifact
- c) Ventricular standstill
- d) Asystole

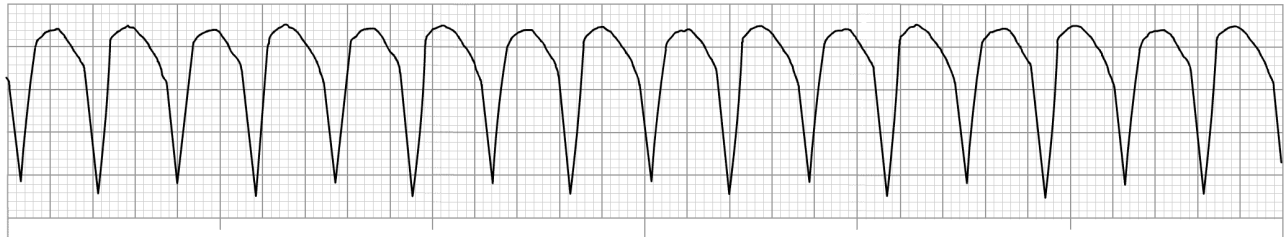
Question 4



This ECG rhythm is called:

- a) Sinus rhythm
- b) Junctional rhythm with artifact
- c) Sinus bradycardia
- d) Paced atrial rhythm

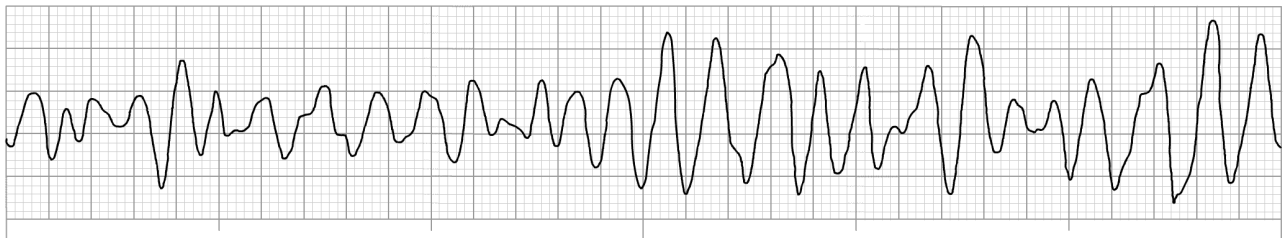
Question 5



This ECG rhythm is called:

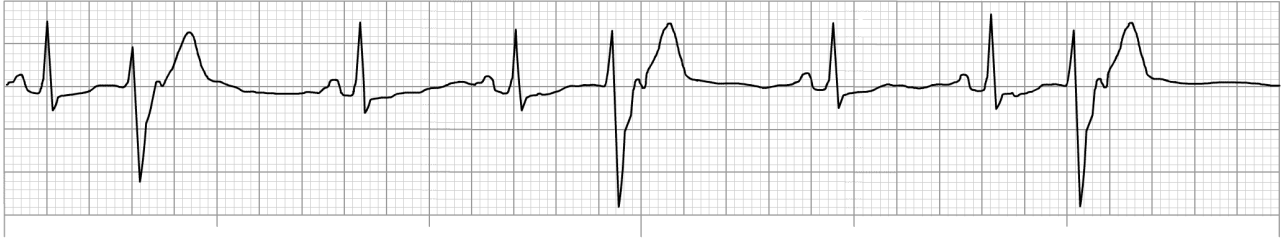
- a) Sinus tachycardia with aberrant intraventricular conduction
- b) Junctional tachycardia
- c) Ventricular tachycardia
- d) Supraventricular tachycardia (SVT)

Question 6



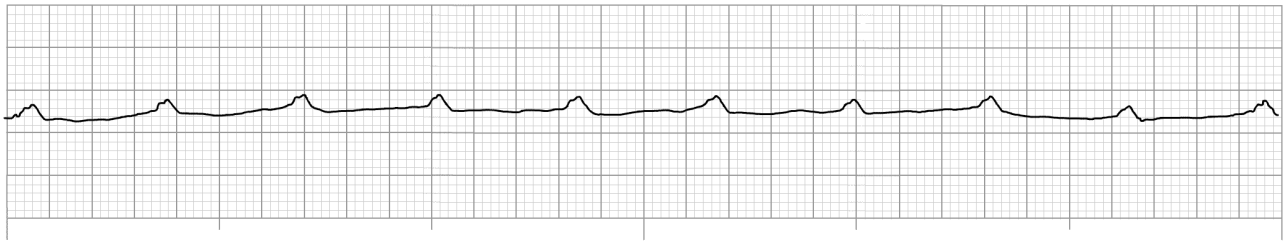
This ECG rhythm is called:

- a) Multifocal atrial tachycardia
- b) Coarse ventricular fibrillation
- c) Ventricular tachycardia
- d) Fine ventricular tachycardia

Question 7

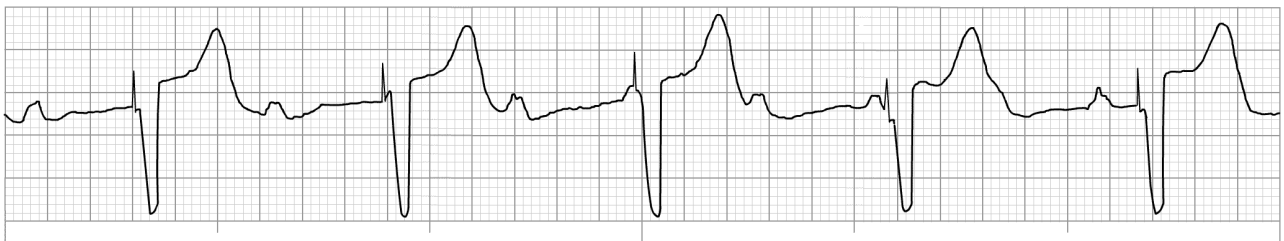This ECG rhythm is called:

- a) Ventricular trigeminy
- b) Junctional trigeminy
- c) Sinus rhythm with premature atrial complexes (PACs)
- d) Sinus arrhythmia with aberrant intraventricular conduction

Question 8

This ECG rhythm is called:

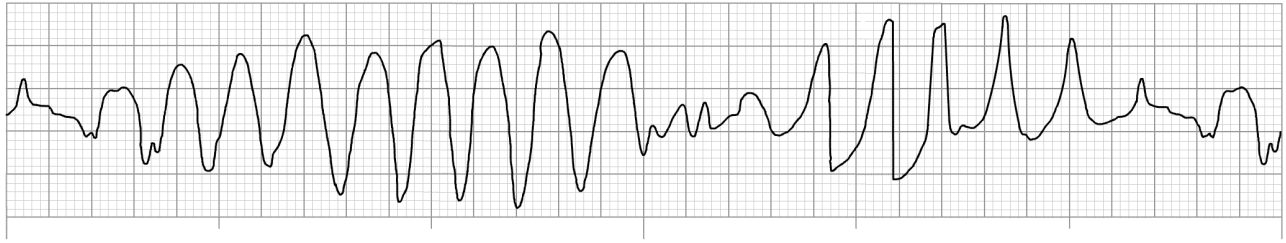
- a) Ventricular standstill
- b) Idioventricular rhythm
- c) Agonal rhythm
- d) Ventricular fibrillation

Question 9

This ECG rhythm is called:

- a) Sinus bradycardia with aberrant intraventricular conduction
- b) Idioventricular rhythm
- c) Paced ventricular rhythm
- d) Junctional rhythm with non-conducted premature atrial complexes

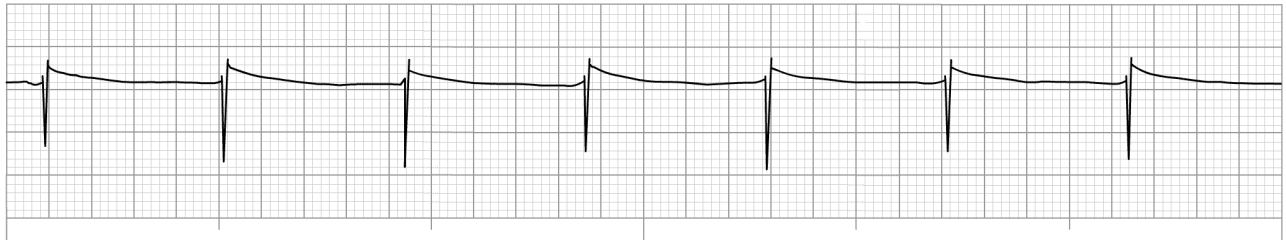
Question 10



This ECG rhythm is called:

- a) Ventricular tachycardia
- b) Multifocal atrial tachycardia
- c) Sinus rhythm with artifact
- d) Torsades de Pointes

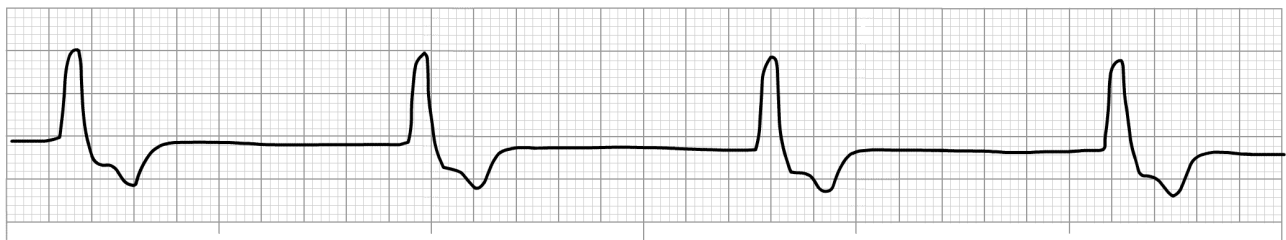
Question 11



This ECG rhythm is called:

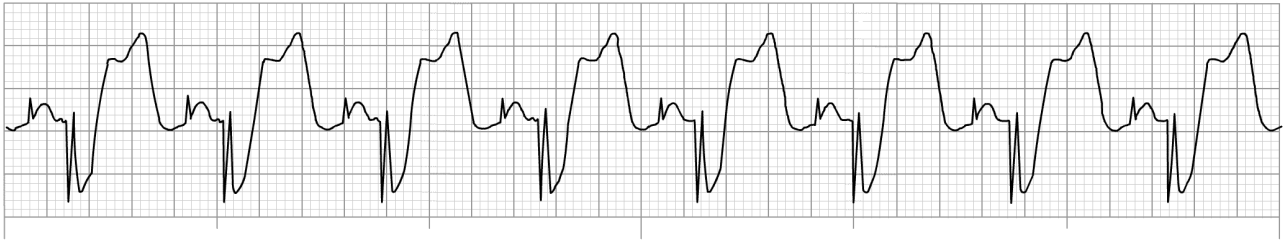
- a) Sinus rhythm
- b) Paced rhythm with complete loss of capture
- c) Accelerated junctional rhythm
- d) Junctional tachycardia

Question 12



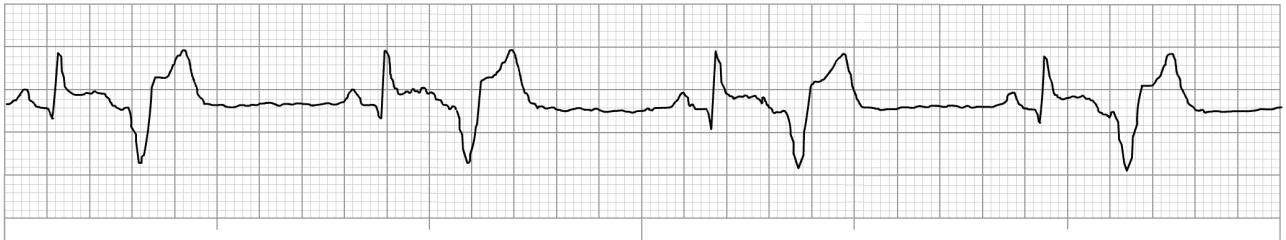
This ECG rhythm is called:

- a) Idioventricular rhythm
- b) Sinus bradycardia
- c) Junctional bradycardia
- d) Paced ventricular rhythm

Question 13

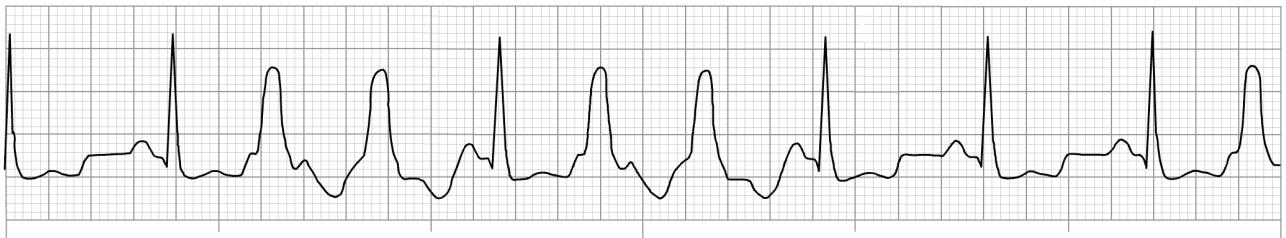
This ECG rhythm is called:

- a) Sinus rhythm
- b) Paced ventricular rhythm
- c) Paced AV sequential rhythm
- d) Accelerated idioventricular rhythm

Question 14

This ECG rhythm is called:

- a) Atrial fibrillation with premature ventricular complexes (PVCs)
- b) Sinus rhythm with premature atrial complexes (PACs)
- c) Ventricular bigeminy
- d) Junctional rhythm with PACs

Question 15

This ECG rhythm is called:

- a) Sinus rhythm with multifocal PVCs
- b) Sinus rhythm with ventricular couplets and a PVC
- c) Accelerated junctional rhythm with PVCs
- d) Sinus rhythm with PACs